

[EVALI](#)

- [Fever](#)
- [Chills](#)
- [Cough](#)
- A hard time breathing
- Shortness of breath
- Chest tightness
- Belly [pain](#)
- Loss of appetite (not hungry)
- [Nausea and vomiting](#)
- [Diarrhea](#)
- Weight loss

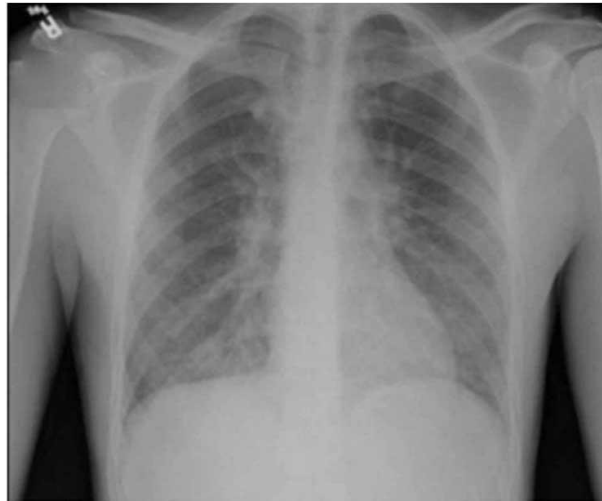


Figure 1_

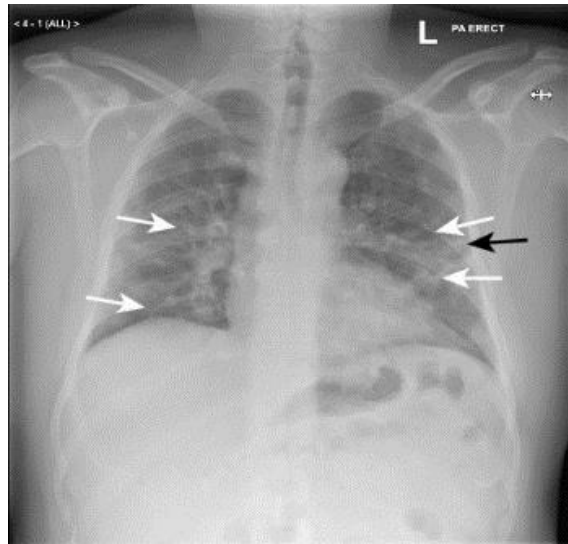
(a) Portable chest X-ray done in the ER on presentation showing bibasilar infiltrates and interstitial prominence.

<https://www.hindawi.com/journals/cripu/2020/6138083/>

Anshika Singh, Qiuxue Tan, Nicole M. Saccone, David H. Lindner, "A Case of Vaping TCH Oil Leading to Vaping Associated Pulmonary Injury: Our Approach to Its Diagnosis, Management, and Recommendations", *Case Reports in Pulmonology*, vol. 2020, Article ID 6138083, 5 pages, 2020. <https://doi.org/10.1155/2020/6138083> [CC BY 4.0](#)

[COVID-19](#)

- Fever or
- chills
- Cough
- difficulty breathing or
- Shortness of breath
- Fatigue
- Muscle or body aches
- Headache
- Nausea or vomiting
- Diarrhea
- New loss of taste or smell
- Sore throat
- Congestion or runny nose



[Fig 1](#)

Ground glass opacity. Posterior-anterior chest radiograph of patient A, a man in his 50s with covid-19 pneumonia. Features include ground glass opacity in both mid and lower zones of the lungs, which is predominantly peripheral (white arrows) with preservation of lung marking. Linear opacity can be seen in the periphery of the left mid zone (black arrow)

This article is made freely available for use in accordance with BMJ's website terms and conditions for the duration of the covid-19 pandemic or until otherwise determined by BMJ. You may use, download and print the article for any lawful, non-commercial purpose (including text and data mining) provided that all copyright notices and trademarks are retained.

<https://bmj.com/coronavirus/usage>